

Submandibular Mass Excision in an Asian Population: A 10-year Review[†]

Dennis YK Chua,¹ MBBS, MRCS (Edin), KO Chan,¹ MBBS, FRCS (Edin), Kuo Sun Lu,¹ MBBS, FRCS (Edin)

Abstract

Objectives: The objectives of this study were to compare the prevalence of submandibular gland neoplasia in an Asian population with a Western population and to evaluate the accuracy of fine needle aspiration cytology (FNAC) and computed tomography (CT) scan in the study of submandibular gland pathologies. **Materials and Methods:** We conducted a 10-year retrospective review of 101 submandibular mass excisions. Data on the demographic profile of patients, clinical features, correlation of fine needle aspiration cytology, CT scans and histology and morbidities related to surgery were collected. **Results:** The prevalence of submandibular gland neoplasia was 27.1%. Most (78.9%) of these were benign. FNAC and CT scans were accurate for benign neoplasia. However, the accuracy of FNAC and CT scans for sialadenitis without sialolithiasis was low. **Conclusion:** The prevalence of submandibular gland malignancy was lower in the Asian population. FNAC and CT scans were accurate for benign neoplasia of the submandibular gland.

Ann Acad Med Singapore 2010;39:33-7

Key words: CT scan, Fine needle aspiration cytology, Submandibular gland diseases, Surgery

Introduction

Submandibular masses are common presenting complaints in the outpatient setting. The differential diagnosis of a submandibular mass lesion can be salivary gland pathology, lymph nodal disease or soft tissue conditions. The more common submandibular gland pathologies include sialadenitis, sialolithiasis, pleomorphic adenoma, lymphoma and carcinomas.¹

The prevalence of malignancy in a submandibular gland neoplasia varies from 33.3% to 78.2%²⁻⁵ in the Western population. Most of the studies quoted a malignancy rate of more than 50%, which was higher than in our practice among an Asian population.

Fine needle aspiration cytology (FNAC) and computed tomography (CT) scans are common investigations that are ordered in the evaluation of submandibular lesions. However, their accuracy varies depending on the submandibular mass pathology.

Materials and Methods

Inclusion and Exclusion Criteria

All 101 patients who underwent a submandibular mass excision from January 1996 to December 2005 at our hospital were identified for this study. Their clinical records

were reviewed and analysed for the following parameters: demographic profile of our Asian patients, clinical features, histology and morbidities related to surgery. FNAC and CT scan results were obtained if present. All submandibular masses excised were sent for histological assessment. Patients with missing case notes were excluded from this study. The patients were followed-up for a minimum of 6 months postoperatively. International Review Board approval was obtained for this research project.

Results

There were a total of 61 males and 40 females. The mean age was 42.3 years with a range of 8 to 84 years. There were 73 Chinese, 19 Malays, 3 Indians and 6 patients of other races similar to our racial distribution. Table 1 shows the different histology of the submandibular mass excised. Seventy-one of the submandibular masses excised were the submandibular gland, while the remaining 30 were from other soft tissue lesions from the submandibular space. The common submandibular pathologies are described below.

Forty-four patients had sialadenitis; amongst whom, 21 had sialolithiasis. The mean age was 45.4 years with a peak incidence between 40 and 50 years (Fig. 1). The male-to-female ratio was 1.3:1. There were 34 Chinese, 8 Malays, 1 Indian and 1 patient of other races (Table 2). Both the

¹ Department of Otolaryngology, Changi General Hospital, Singapore

Address for Correspondence: Dr Dennis YK Chua, Department of Otolaryngology, Changi General Hospital, 2 Simei Street 3 Singapore 529889.

Email: dennis.chua.yk@gmail.com

[†] Presented at the American Academy of Otolaryngology Annual Meeting 2006, Toronto, Ontario, Canada, 17-20 September 2006.

Table 1. Histology of Submandibular Mass Excised

Histology of submandibular mass excised	No.
1 Sialadenitis/Sialolithiasis	44
2 Pleomorphic adenoma	14
3 Necrotising granulomatous inflammatory TB	6
4 Ranula	5
5 Kimura's disease	3
6 Adenoid cystic carcinoma of submandibular gland	2
7 Normal gland with previous abscess	3
8 Lymphangioma	2
9 Benign mucus retention cyst/Sialadenitis	2
10 Myoepithelial carcinoma of submandibular gland	1
11 Abscess	1
12 Basal cell adenoma of submandibular gland	1
13 Benign cyst/Sialadenitis	1
14 Burkitt's lymphoma	1
15 Cavernous haemangioma	1
16 Granulomatous lymphadenitis ?normal gland	1
17 Haemorrhage/Sialadenitis	1
18 Hyperplastic lymph node with granulomatous inflammation	1
19 Hyperplastic lymph node with normal gland	1
20 Lymphoma	1
21 Metastatic undifferentiated carcinoma	1
22 Mucocele	1
23 Nodular fasciitis/FS:Spindle cell tumour of submandibular gland	1
24 Poorly differentiated metastatic secondaries from lung cancer	1
25 Reactive lymphoid hyperplasia	1
26 Ruptured epidermal cyst	1
27 Salivary duct carcinoma	1
28 Schwannoma	1
29 Vascular malformation	1
Total	101

left and right sides were equally represented with 1 patient having bilateral symptoms. There were equal numbers of patients with sialadenitis/sialolithiasis who presented with a painless mass (20 patients) and a painful mass (20 patients), which was worse during meals. Three patients had a discharge from the floor of the mouth and 1 patient had a floor of mouth ulcer with a palpable stone as the only complaint (Fig. 2). The average duration of clinical symptoms prior to consultation was 9.8 months and 50% of patients presented to the clinic within 3 months. The duration of symptoms ranged from 5 days to 5 years.

Table 2. Racial Distribution of Patients with Sialadenitis/Sialolithiasis

Race	No.	%
Chinese	34	77.3
Malay	8	18.2
Indian	1	2.3
Others	1	2.3

There were 19 patients (27.1% of all 70 patients with submandibular gland pathology) with neoplastic salivary gland disease. Fifteen out of the 19 patients had benign neoplasia of the submandibular gland. Fourteen of these were due to pleomorphic adenoma. There was a case of basal cell adenoma.

There were 9 Chinese, 4 Malays and 1 Indian patients. The male-to-female ratio was 1.8:1, with the disease appearing only in the second decade and peaking in the fifth decade of life (Fig. 3). Sixty-four per cent of the patients presented within 3 months of symptoms appearance and all patients presented with a painless mass. Nine patients had pleomorphic adenoma on the left side and 5 had it on the right.

There were 2 patients with adenoid cystic carcinoma of the submandibular gland, 1 with myoepithelial carcinoma possibly arising from pleomorphic adenoma and 1 patient with a spindle cell tumour.

FNAC Results

FNAC was done for 46 patients. It was not suitable for interpretation in 18 (39.1%) patients as it was insufficient or contained only blood. Among the 28 (60.9%) samples suitable for interpretation, only 15 (53.6%) patients had correct diagnosis.

FNAC was accurate in 6 out of 8 (75%) patients with pleomorphic adenoma. The other 2 were mis-diagnosed to have sialadenitis, which could have been a co-existing problem.

FNAC performed in 7 patients with sialadenitis were inaccurate. Three of these were diagnosed as normal while the other 3 showed non-specific features of reactive lymphoid hyperplasia. One was incorrectly diagnosed as Warthin's tumour.

CT Scan Results

CT scan of the neck was done for 57 patients. Correct diagnoses were obtained in 35 (61.4%) patients. Among the 44 patients with sialadenitis, CT scan of the neck was done for 21 patients and correct diagnoses were obtained only in 13 patients (61.9%) (Table 3). It was highly accurate in diagnosing sialadenitis with sialolithiasis, achieving the diagnosis in 11 out of 12 patients (91.7%). One patient was

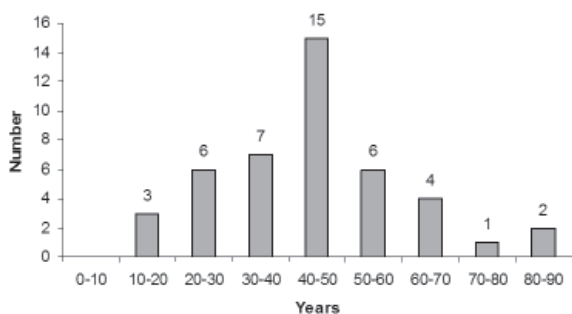


Fig. 1. Age distribution of patients with sialadenitis/sialolithiasis.

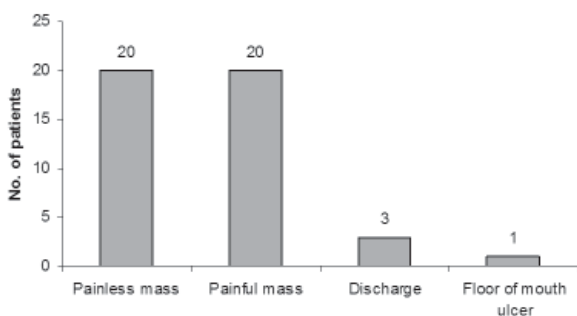


Fig. 2. Presenting symptoms of patients with sialadenitis/sialolithiasis.

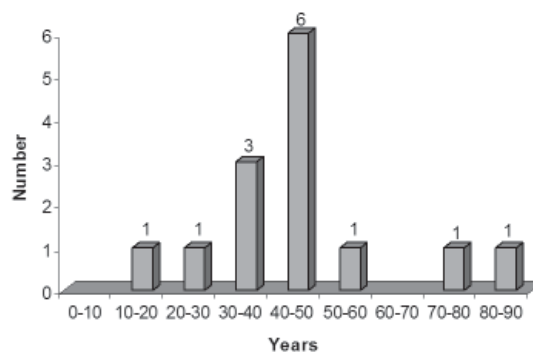


Fig. 3. Age distribution of patients with pleomorphic adenoma.

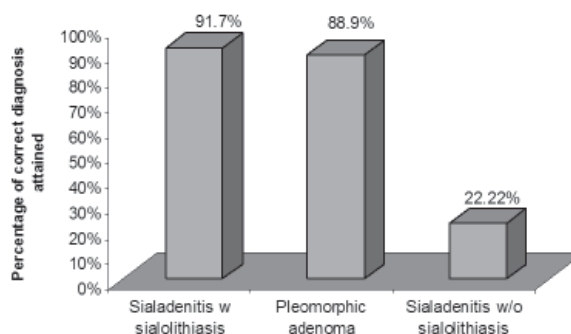


Fig. 4. Accuracy of CT scans.

incorrectly diagnosed as having a normal submandibular gland on CT scan. However, its accuracy dropped for sialadenitis without sialolithiasis as only 2 out of 9 (22.2%) patients were correctly diagnosed on CT scan (Fig. 4). Overall, there was a false negative rate of 38.1% and a false positive rate of 0% when using CT scans in patients with sialadenitis with or without sialolithiasis. CT scan was accurate in 8 out of 9 patients with pleomorphic adenoma. One patient was incorrectly diagnosed with a malignant cervical lymph node.

Seventeen out of the 31 patients with submandibular masses not due to submandibular gland disease, had lymph node pathology. The most common disease was tuberculous lymphadenitis and all patients recovered with anti-tuberculosis treatment. Three patients had Kimura’s disease and were treated with long-term oral corticosteroids postoperatively. The remaining 13 patients had a myriad of diseases (Table 1).

Postoperative Complications

Our complication rate was 12.9% (13 out of 101 patients) for all submandibular excisions. Neuropraxia of the marginal mandibular branch of the facial nerve was the most common, occurring in 5 out of 13 patients and lingual nerve neuropraxia occurred in 3 out of 13 patients. One patient had both lingual nerve and marginal mandibular nerve neuropraxia. All patients recovered from the neuropraxia within 6 months. Wound haematoma requiring a return to

Table 3. Provisional Diagnosis on CT Scans in Patients with Sialadenitis/Sialolithiasis

CT scan diagnosis (number)	Actual histology
Sialadenitis/Sialolithiasis (11)	Sialadenitis/Sialolithiasis
No abnormality (1)	Sialadenitis/Sialolithiasis
Sialadenitis (2)	Sialadenitis
Pleomorphic adenoma (2)	Sialadenitis
No abnormality (1)	Sialadenitis
Acinic cell carcinoma (1)	Sialadenitis
Cystic lesion (1)	Sialadenitis
Lymphadenopathy (1)	Sialadenitis
Plunging ranula (1)	Sialadenitis

the operating theatre to secure haemostasis occurred in 3 patients. All 3 haematomas were due to failure to ligate a branch of the facial artery and they all resolved after the appropriate vessels were tied off (Table 4). There was 1 case of postoperative xerostomia which resolved spontaneously after 1 month.

Discussion

Submandibular Tumours: Malignant versus Benign Rates

The prevalence of malignancy in a submandibular gland tumour varies from 33.3% to 78.2%²⁻⁵ in Western

Table 4. Postoperative Complication Rate

Postoperative complication rate	
Marginal mandibular nerve neuropraxia	5
Lingual nerve neuropraxia	3
Lingual nerve/marginal mandibular nerve neuropraxia	1
Wound haematoma	3
Xerostomia	1
Total no. of patients with postoperative complications	13

populations. We believe this wide range could depend on where the data are collected. A larger proportion of malignant lesions may be expected in a tertiary head and neck centre. Most of the studies quoted a malignancy rate of more than 50%, which is higher in our practice in a secondary referral hospital among an Asian population.

Our prevalence of malignant submandibular gland tumours is low (21.1%) compared with most figures quoted in the literature. In a previous study from Singapore in a tertiary centre, Goh et al¹ found that 13.5% of submandibular gland tumours were malignant. This suggests that Asians have a lower prevalence of malignant submandibular gland tumours.

Correlation of FNAC and Histology for Sialadenitis/Pleomorphic Adenoma

In our experience, the correlation between FNAC and histology was accurate for benign neoplasms. There was good correlation in 6 out of 8 cases of pleomorphic adenoma. The remaining 2 cases had features of sialadenitis on FNAC which could have been a co-existing problem.

Most studies on correlation between FNAC and histology of salivary glands have shown that FNAC was most accurate for benign neoplastic lesions. However, the diagnostic accuracy of FNAC for non-neoplastic lesions and malignant lesions was poor. Atula et al⁶ quoted a 29% sensitivity for malignant lesions of the submandibular gland. Cohen et al⁷ quoted a positive and negative predictive value of 83% and 88%, respectively, in the use of FNAC for a benign neoplasm of a major salivary gland. However for a non-neoplastic lesion, its predictive value was only 47%. Therefore, the predictive value of a negative FNAC was low. This showed that FNAC was a valuable adjunct in the evaluation of a patient with submandibular gland neoplasia. However, it forms only part of the clinical picture and decision on surgery should not be based only on the FNAC.

Correlation of CT Scan and Histology for Sialadenitis/Pleomorphic Adenoma

CT scan is a common investigation used in the evaluation of submandibular masses. In our experience, we found

CT scan to be useful in the diagnosis of pleomorphic adenoma of the submandibular gland (accuracy of 88.9%) and sialadenitis with sialolithiasis (accuracy of 91.7%). Its accuracy decreased for sialadenitis without sialolithiasis. The relatively high false negative rate of 38.1% in diagnosing patients with sialadenitis means that care must be taken when interpreting a negative CT scan of a patient with clinical diagnosis of sialadenitis as the CT scan diagnosis could be wrong. However with a false positive rate of 0% for sialadenitis, the CT scan diagnosis can be relied on if the diagnosis is that of sialadenitis. However, it should be remembered that reactive sialadenitis can be a co-existing problem in various submandibular gland diseases.

There are few papers in the literature that studied the usefulness of CT scans in submandibular gland diseases. Similar to FNAC, CT scans are useful adjuncts in the evaluation of submandibular gland diseases.

Postoperative Complication

Submandibular mass excision is a relatively safe operation. From the literature, the morbidity rate ranges from 4.3%¹ to 36%.⁷ Neurological complications are the most common, with risk of injury to the marginal mandibular branch of the facial nerve, lingual nerve and the hypoglossal nerve. Our complication rate of 12.9% compares favourably with figures from other centres. Neoplastic lesions do not seem to have a higher complication rate although it is difficult to comment from the small number of complications.

Correlation of Symptoms and Lesions

From our experience, a painful submandibular mass was usually due to inflammatory conditions such as sialadenitis, lymphadenitis or submandibular gland abscess. Neoplastic diseases of the submandibular gland usually presented as a painless mass. Among the 31 patients who presented with a painful mass, only 1 was due to a neoplasia (salivary duct carcinoma). All other neoplastic diseases presented as a painless mass.

All 14 patients with pleomorphic adenoma presented with

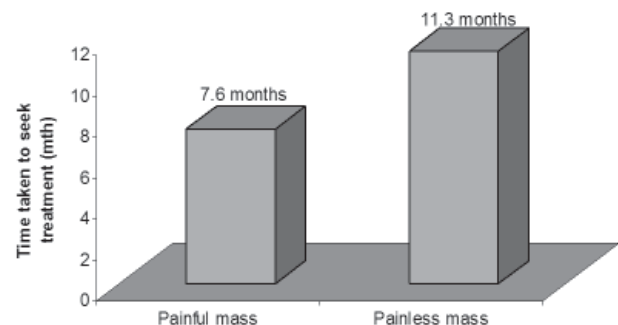


Fig. 5. Time taken for patients to seek treatment.

a painless mass. Twenty of the 44 patients with sialadenitis/sialolithiasis presented with a painful mass and another 20 had a painless mass. Patients who experienced pain tended to seek treatment earlier (Fig. 5). Sixty-five per cent of patients with a painful mass sought medical treatment within 3 months compared to only 35% of patients with a painless mass.

Conclusion

The prevalence of malignant submandibular tumours seemed to be lower in an Asian population. CT scans were accurate for sialadenitis with sialolithiasis and pleomorphic adenoma of submandibular glands. FNAC was a useful tool, especially for the diagnosis of benign neoplastic lesions of the submandibular gland. Its accuracy and predictive value was low in non-neoplastic conditions. Submandibular mass excision was a relatively safe procedure although neurological complications may occur. However, these

were usually temporary and resolved in a few months with no residual effects.

REFERENCES

1. Goh YH, Sethi DS. Submandibular gland excision: a five-year review. *J Laryngol Otol* 1998;112:269-73.
2. Weber RS, Byers RM, Petit B, Wolf P, Ang K, Luna M. Submandibular gland tumors. Adverse histologic factors and therapeutic implications. *Arch Otolaryngol Head Neck Surg* 1990;116:1055-60.
3. Gallina E, Gallo O, Boccuzzi S, Paradiso P. Analysis of 185 submandibular gland excisions. *Acta Otorhinolaryngol Belg* 1990;44:7-10.
4. Crabtree GM, Yarrington CT. Submandibular gland excision. *Laryngoscope* 1988;98:1044-5.
5. Lukasik S, Szuber D, Mazur W, Drewienkiewicz E. Tumors of the submandibular gland. *Otolaryngol Pol* 1995;49Suppl 20:242-4.
6. Atula T, Grenman R, Laippala P, Klemi PJ. Fine-needle aspiration cytology of submandibular gland lesions. *J Laryngol Otol* 1995;109:853-8.
7. Cohen EG, Patel SG, Lin O, Boyle JO, Kraus DH, Singh B, et al. Fine-needle aspiration biopsy of salivary gland lesions in a selected patient population. *Arch Otolaryngol Head Neck Surg* 2004;130:773-8.